

PREVENTION OF ETHAMBUTOL INDUCED CHANGES BY MEMANTINE IN OPTIC NERVE OF RABBIT

M. ZUBAIR, M. TAHIR, T. H. SHEIKH, K. P. LONE. W. SAMEE AND BUSHRA MUNIR
Department of Anatomy, University of Health Sciences, Lahore – Pakistan

ABSTRACT

This study was designed to evaluate the prevention of ethambutol (EMB) induced toxicity in optic nerve by memantine. Forty optic nerve specimens were obtained from twenty New Zealand albino rabbits; these were divided into four groups, each comprising five animals. Group A, was given distilled water according to their weight, in addition to water ad libitum. Group B was treated with EMB 100 mg/kg/day and groups C and D were treated with memantine (MEM), 1 and 5 mg/kg/day respectively, in addition to EMB for four weeks which was given one hour before administering EMB. Optic nerves were removed after sacrificing the animals under anaesthesia and processed for histological examination. It was observed that the preparations from group B showed marked vacuolation of axoplasm (205.60 ± 49.33) the difference was statistically significant when compared with groups A (2.80 ± 0.22), C (2.80 ± 0.98) and D (1.33 ± 0.37), It was concluded that EMB induced vacuolar changes could be prevented by using MEM.

Key words: *Ethambutol, memantine, optic nerve, vacuoles.*

Ethambutol (EMB) had been reported to induce toxic ocular effects producing bulbar and retro-bulbar neuritis, manifested as painless, symmetrical and progressive loss of vision, central or caecentral scotoma and dyschromatopsia.^{1,2,3} EMB-produces degeneration and loss of optic nerve axons having diameter of 1 μ m or less.⁴ Different experimental animals, when treated with toxic doses of EMB, revealed multiple cystic lesions, mild demyelination, axonal fragmentation, myelin like structure in the axoplasm along with central necrosis and inflammatory changes in the optic nerve.⁵

Damage to the retinal ganglion cell bodies and their axons, seen with EMB, is strikingly similar to that produced by excessive levels of excitatory amino acids especially glutamate (GTM) that acts as a neurotransmitter in the human central nervous system (CNS). It is stored in presynaptic vesicles and normally interact with specific post synaptic receptors like N-methyl-D-aspartic acid (NMDA) present in neurons and retinal ganglion cells (RGC)⁶ to mediate many normal neurological and physiological functions, however, excessive activation of these receptors results in injury or death of neurons.^{7,8} GTM antagonists, therefore, are presumed to prevent ethambutol induced toxicity.⁹ Memantine (MEM), is reported to be an open channel GTM antagonist that acts as neuroprotective agent at multiple sites.^{10,11} It was reported that MEM provided neuroprotection in vivo, from a variety of toxic conditions produced by

overactivity of GTM, such as amyloid degeneration, inhibition of mitochondrial function and ischaemia to the brain.¹² Activity of MEM as GTM antagonists had been reported in experiments designed to protect retinal ganglion cells from its toxicity in rats produced by oral administration of ethambutol⁶ or intravitreal glutamate injections.⁷ It also prevents NMDA receptor mediated neurotoxicity.¹³ Protective effect of MEM on the optic nerve was observed in rabbits in which ischaemia was induced in optic nerve, by delivering Endothelin, to the perineural region of the optic nerve.¹⁴ MEM has also been proven to be safe and effective for reducing the functional and structural loss of RGCs associated with experimental glaucoma induced by increased levels of GTM in monkeys.^{15,16}

MATERIAL AND METHODS

Twenty, New Zealand, albino rabbits of either sex, weighing 1- 2 kg were procured from the Veterinary Research Institute, Lahore. Each rabbit was housed in a separate cage under controlled conditions of temperature 20 ± 0.5 °C, humidity (50 ± 10 %) and 12 hours light and dark cycle. They were fed on standardized diet and water ad libitum; the animals were divided into four groups.

Group A served as a control, and was given weight related distilled water in addition to water ad libitum for the experimental period of four weeks.

Group B was treated with EMB 100 mg / kg / day, group C was treated with MEM 1 mg / kg /

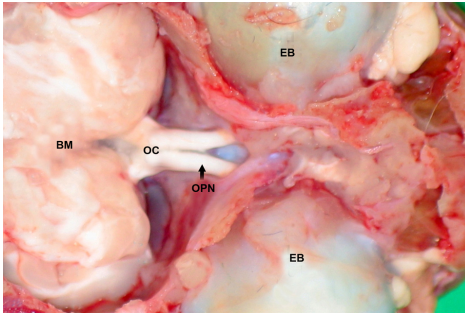


Fig. 1: Photograph of rabbit showing optic nerve in situ OPN, optic chiasma (OC), eye ball (EB) and brain (BM), after removing frontal lobe of cerebrum and the floor of anterior cranial fossa.

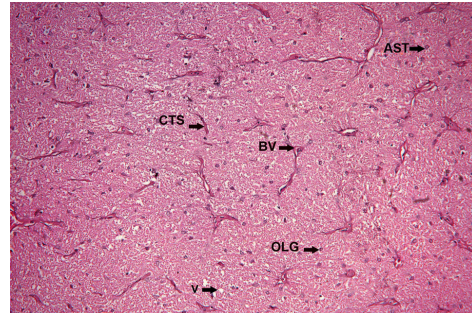


Fig. 5: Optic nerve section from group D, showing structure and vacuoles (V) comparable to those in group A, astrocytes (AST), oligodendrocyte (OLG), blood vessel (BV) connective tissue septa (CTS) H & E stain, X 100.

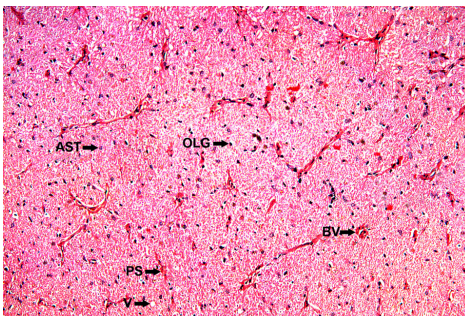


Fig. 2: Optic nerve from group A showing, pial septa (PS), blood vessels (BV), oligodendrocyte (OLG), astrocyte (AST) and a few small sized vacuoles (V) H & E stain, X 100.

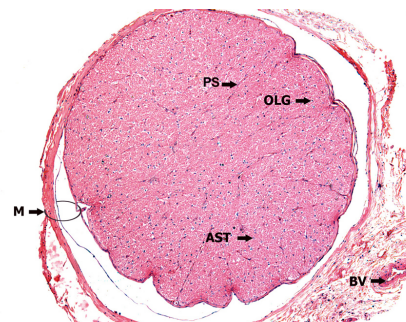


Fig. 7: Cross section of optic nerve from group A having 1.13 ± 0.03 mm as its diameter and showing covering meninges (M), blood vessels (BV) oligodendrocytes (OLG), astrocytes (AST) and pial septa (PS). H & E stain, X 50.

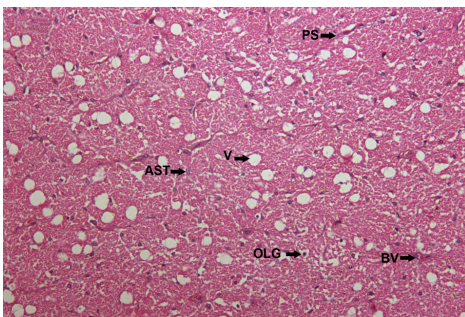


Fig. 3: Optic nerve section from group B, showing same features as in Fig. 2, except for a large number of vacuoles (v), of different sizes in its neuritis astrocyte (AST), oligodendrocyte (OLG), blood vessel (BV), pial septa (SP) H & E stain, X 100.

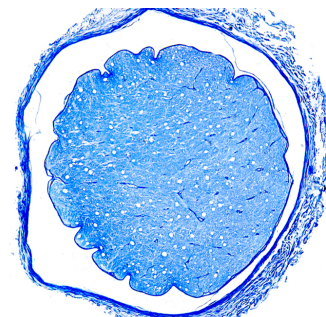


Fig. 8: Cross section of rabbit optic nerve from group B, showing reduction in diameter to 1.03 ± 0.03 mm as its diameter LFB & CV stain, X 50.

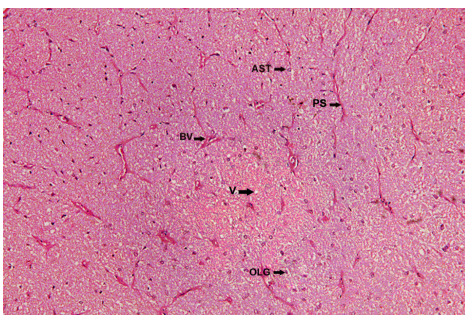


Fig. 4: Optic nerve section from group C, showing usual structure of optic nerve and a few vacuoles (V) comparable to those in group A. Oligodendrocyte (OLG), blood vessel (BV) astrocytes (AST) pial septa (PS) H & E stain, X 100.

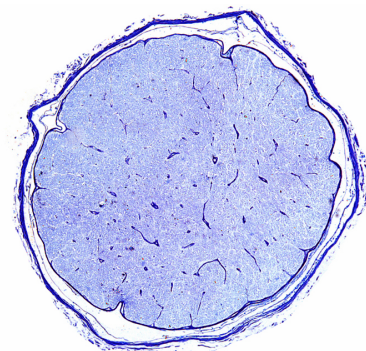


Fig. 9: Cross section of rabbit optic nerve from group C, having 1.07 ± 0.03 mm as its diameter. L.F.B. & C.V. stains, X 50.

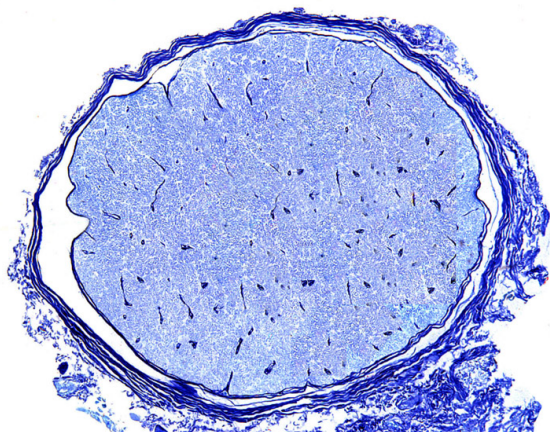


Fig. 10: Cross section of rabbit optic nerve from group D, having 1.10 ± 0.03 mm as its diameter. L.F.B. & C.V. stains, X 50.

day and group D was given MEM 5 mg / kg / day both one hour before giving EMB.

Animals were sacrificed under anaesthesia. Both optic nerves were dissected¹⁷ (Fig. 1) and removed as a single piece by incising them proximal to the optic chiasma and distal to the eye ball; processing was carried out for histological examination in a usual way and stained with hematoxylin and eosin. To demonstrate the myelin sheath, luxol fast blue (LFB) and cresyl violet (CV) stains were used separately.

The slides were examined under the light microscope (Leica, DM 1000) at different magnifications and observations were recorded. The optic nerve axoplasm was seen to be riddled with large number of vacuole which were counted per unit area of 0.50 mm^2 after calibrating the ocular graticule with stage linear micrometer, using X40 objective. Diameter of the optic nerve was measured after calibrating ocular micrometer with stage linear micrometer, using X10 objective.

STATISTICAL ANALYSIS

The data was entered and analysed using SPSS version 15 Mean \pm are given for quantitative variables. One way ANOVA was applied to observed group mean differences, post – HOC Tuckey test was applied to observe which group mean differed and a p-value of < 0.05 was considered as statistically significant.

RESULTS

Light microscopic examination revealed that the optic nerve of rabbit was surrounded by three layers of meninges; thin branching septa, arising from pia matter, extended into the nerve. The neurites were supported by astrocytes and oligo-

dendrocytes. Invariably all sections showed branches of central retinal artery inside the pial septa of the optic nerve (Fig. 2). Demyelination, inflammatory changes and myelin like structure, described earlier in the axoplasm of optic nerve fibers, were conspicuous by their absence in all our preparations.

All preparations from control and experimental groups showed vacuoles of different sizes. Group A exhibited vacuoles which were 2.80 ± 0.22 per 0.50 mm^2 , (Fig. 2), and vacuoles varying from 205.60 ± 49.33 were demonstrated in the preparations from group B (Fig. 3); groups C and D revealed a marked decrease in number of Vacuoles and varied from 2.80 ± 0.98 and 1.33 ± 0.37 respectively, per 0.50 mm^2 (Fig. 4, 5 and 6). These changes in number of vacuoles were statistical significant (p-value 0.00)

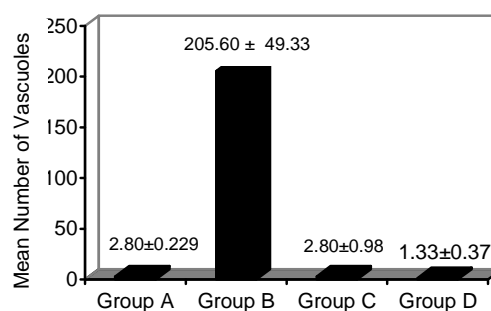


Fig. 6: Bar chart showing mean and standard error of mean in number of vacuoles in groups A, B, C and D.

Diameter of optic nerve from all preparations of the experimental group B (1.03 ± 0.03 mm) decreased as compared to those in group A (1.13 ± 0.03 mm) as shown in Figs. 7 and 8, while all sections from groups C and D showed an increase in diameter of optic nerve (1.07 ± 0.03 & 1.10 ± 0.03 mm respectively) as compared to that of group B but comparable to that in group A (Fig. 9 and 10). The difference in the mean diameter of optic nerve of the control when compared with those from the experimental groups were statistically insignificant p value > 0.05 (Fig. 11).

DISCUSSION

In the current study, vacuoles were observed in all preparations obtained from experimental and control groups. The number of vacuoles in group B (205.60 ± 49.33) was markedly increased when compared to that in group A (2.80 ± 0.22); this difference was statistically significant (p-value =

0.001). The number of vacuoles in group C (2.80 ± 0.98) and group D (1.33 ± 0.37) and when these were compared individually with those in group B (205.60 ± 49.33), the difference was found to be a statistically significant (p -value = 0.001) The result of our investigation support the earlier observations.^{5,18} However, the results reported by Cappiello are at variance to those of our; they reported multiple histological changes in brain and other viscera of dogs, produced by EMB but could not detect vacuolation in optic nerve.¹⁹

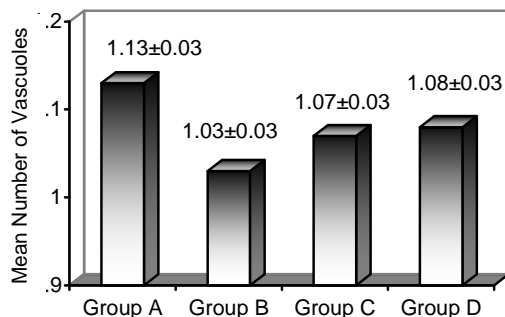


Fig. 11: Bar chart showing mean and standard error of diameter of optic nerve in groups A,B,C and D.

These vacuoles indicate axonal degeneration induced by EMB mediated increased Ca^{++} influx activating certain intracellular enzymes causing cell membrane damage, digestion of cytoskeletal proteins and ATP depletion, which results in failure of $Na^+ K^+$ pump leading to cellular swelling, anaerobic glycolysis, impaired protein synthesis and accumulation of lipids inside the cell that microscopically appear like vacuoles.²⁰ Other possible mechanism stipulated the metabolites of EMB forming a complex with Zn and Cu which enters the axons and enhances the axonal dilatations (vacuolation) process.¹⁸

The difference in number of vacuoles in groups C and D when compared to those in groups B, indicate that MEM had successfully prevented the toxic effects of EMB on the optic nerve. The inferences was further supported by comparing the number of vacuoles in experimental groups C and D with those from the control group, the difference was statistically insignificant, ($p > 0.05$). The microscopic pictures of optic nerve from groups C & D were very close to those from group A. The protective effect of MEM on EMB induced changes in the optic nerve had not been studied sufficiently. Jogn⁶ and others, however, reported that MEM protected the retinal ganglion cells from EMB toxic effects mediated through over stimu-

lation of NMDA receptors by the hyperactivity of endogenous GTM.⁶ Comparable mechanism had been reported to prevent glaucoma, ischemic, acute or degenerative lesions of neurons, as these were experimentally protected by use of GTM antagonist, memantine.^{12,14}

Diameter of the optic nerve in group B was 1.03 ± 0.03 mm and was found to have decreased, when compared to those from groups A, C and D, where the diameter of optic nerve was 1.13 ± 0.03 , C 1.07 ± 0.03 and D 1.10 ± 0.03 mm respectively. These changes were found statistically insignificant ($p > 0.05$).

Demyelination, inflammatory changes, and myelin like structure in the axoplasm have already been reported in different animals;^{5,18} our investigations did not show these changes. This difference could possibly be explained on account of variable dose of EMB and duration of the experimental period. However, results comparable to our observations had been reported in 1987.¹⁸

Our findings and those of others in collateral studies indicate that memantine protects EMB induced changes in optic nerve of the rabbit. The results may be extended to its clinical application for preventing ocular complications induced by EMB in cases of patient receiving the drug for treatment of tuberculosis.

ACKNOWLEDGEMENTS

We gratefully acknowledge the help and support from Malik Hussain Mubasher V.C. UHS, and Mr, Waqas Samee, the biostatistician and we also thanks Naveed Abbas, the lab. technologist, for his practical assistance and Muhammad Ramzan, Assistant staff officer and his assistance in formulating the work.

REFERENCES

1. Lim SA. Ethambutol associated optic neuropathy. *Ann Acad Med Singapore*. 2006; 35: 274-8.
2. Zoumalan CI, Agarwal M, Sadun AA. Optical coherence tomography can measure axonal loss in patients with ethambutol-induced optic neuropathy. *Graefe's Arch Exp Ophthalmol*. 2005; 243: 410-16.
3. Choi SY, Hwang JM. Optic neuropathy associated with ethambutol in Koreans. *Koreans J. Ophthalmol*. 1997; 11: 106-10.
4. Hwang JM, Kim J, Park SS. Leber's hereditary optic neuropathy mutations in ethambutol induced optic neuropathy. *J Neurol*. 2003; 250: 87-9.
5. Lessell S. Histopathology of experimental ethambutol intoxication. *Invest Ophthalmol Vis Sci*. 1976; 15: 765-9.
6. Heng JE, Vorwerik CK, Lessell E, Zurakowski D, Levin LA, Dreyer EB. Ethambutol is toxic to Retinal Ganglion Cells via an Excitotoxic Pathway. *Invest. Ophthalmol Vis. Sci*. 1999; 40 (1): 190-6.

7. Vorwerk CK, Lipton SA, Zurakowski D, Hymen BT, Sabel BA, Dreyer EB. Chronic low-dose glutamate is toxic to retinal ganglion cells. Toxicity blocked by memantine. *Invest Ophthalmol Vis Sci.* 1996; 37: 1618-24.
8. Cosman KM, Porsteinsson AP. Glutamate in the neurobiology and treatment of dementias. *Prim psychiatry.* 2006; 13: 48-55.
9. Vorwerk CK, Naskar R, Schuettauf F, Zuradowski D, McDermott LM, Quinto KM, et al. Excitotoxicity can be mediated through an interaction within the optic nerve; activation of cell body NMDA receptors is not required. *Vet. Ophthalmol.* 2001; 4: 201-4.
10. Muir W, Keith, Lees KR. Clinical experience with excitatory amino acid antagonist drugs. *Stroke.* 1995; 26: 503-13.
11. Quack G, Kornhuber J. Cerebrospinal fluid and serum concentrations of the N- Methyl-D-Aspartate (NMDA) receptor antagonist memantine in man.
12. Danysz W, Parsons CG. The NMDA receptor antagonist memantine as a symptomatological and neuroprotective treatment for Alzheimer's disease: pre-clinical evidence. *Int J Geriatr Psychiatry.* 2003; 18: S23-32.
13. Chen HV, Pellegrini JW, Aggarwal SK, Lei SZ, Warach S, Jensen FE, et al. Open-channel block of N-Methyl-D-Aspartate (NMDA) responses by memantine: Therapeutic advantage against NMDA receptor-mediated neurotoxicity. *J Neurosci Nurs.* 1992; 12: 4427-36.
14. Kin TW, Kim DM, Park KH, Kim H. Neuroprotective effects of memantine in a rabbit model of optic nerve ischemia. *Korean J Ophthalmol.* 2002; 16: 1-7.
15. Hare WA, WoldeMussie E, Lai RK, Ton H, Ruiz G, Cbun T, et al. Efficacy and safety of memantine treatment for reduction of changes associated with experimental glaucoma in monkeys, I: Functional measures. *Invest Ophthalmol Vis Sci.* 2004; 45: 2625-39.
16. Hare WA, Wolde Mussie E, Lai RK, Ton H, Ruiz G, Cbun T, et al. Efficacy and safety of memantine treatment for reduction of changes associated with experimental glaucoma in monkeys, I: Structural measures. *Invest Ophthalmol Vis Sci.* 2004; 45: 2640-51.
17. Romanes GJ. *Cunningham's Manual of Practical Anatomy.* Vol. 3. 15th ed. New York: Oxford; 2004.
18. Noche RR, Nicolas MG, Biochem MS, Gonzaga NC. A Study of Optic neuritis caused by Ethambutol in Rabbits. *PJMI* 1987; 17: 42-6.
19. Capiello VP, Layton WM. A one year study of ethambutol in dogs: Results of gross and histopathologic examinations. *Toxicol Appl Pharmacol.* 1965; 7: 844-9.
20. Kumar V, Abbas AK, Fausto N, Mitchell R. *Robbin's Basic Pathology.* 8th edition. Philadelphia: Elsevier; 2007.